

extending a foot or so beyond the body on all sides. The weight of the earth above had broken in the skull along the sutures and also warped it out of shape, so that no measurements could be made, but as it lay in position the effect of its shape seemed markedly brachycephalic.

*Skeleton No. 3.*—In this same terrace I, we came upon two other skeletons at the same level (+28 feet). One, very small, was left unexcavated in the east wall of the terrace, but the other, also in the east wall, I laid bare. The main axis of the body was southwest and northeast as far as could be determined by the few bones preserved. The body had evidently lain on its back, with the skull propped up in such a way that it now was set squarely on its base and lower jaw fitted over the first two vertebræ so as almost to suggest a dislocation of the neck. The left leg was extended straight down the main axis northeast from the skull, but the right knee was slightly bent and thrown over to the right above it. Only six of the ribs remained, all on the left side, and the top of the cranium had broken down, leaving only the side-walls and lower portions in place. (See fig. 536.)

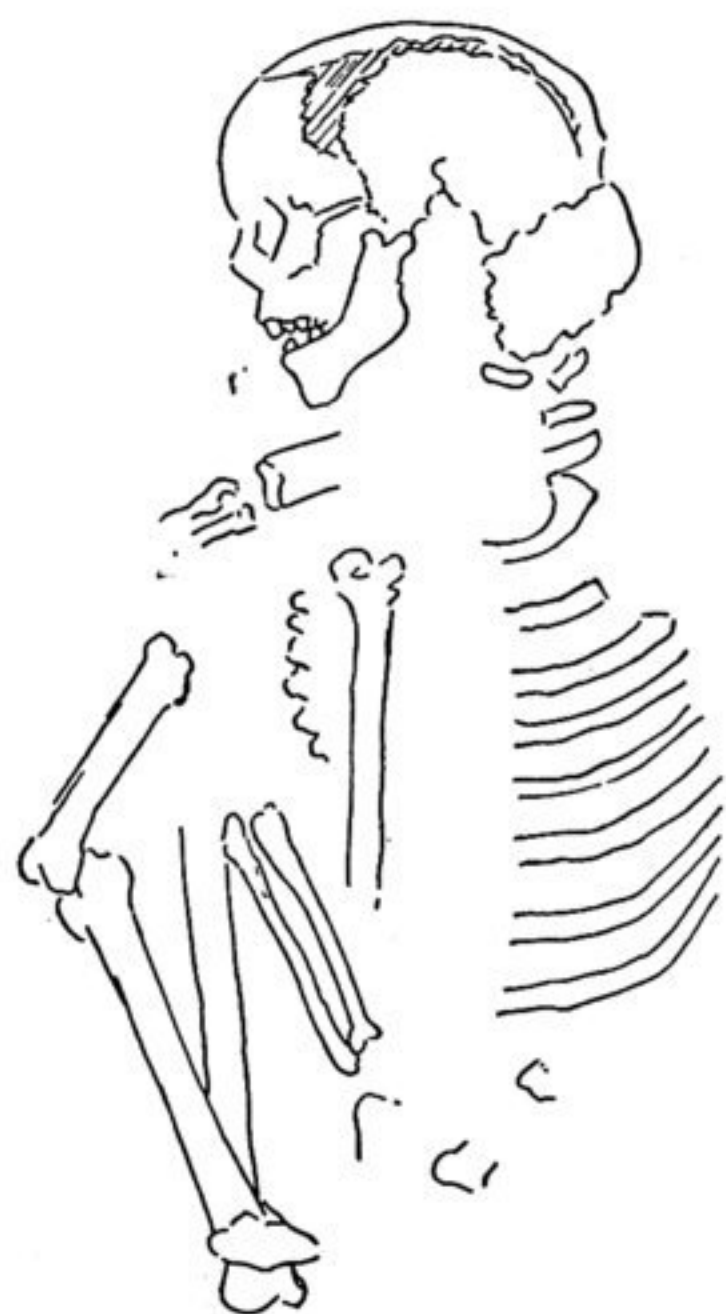


Fig. 534.—No. 5, Terrace I.

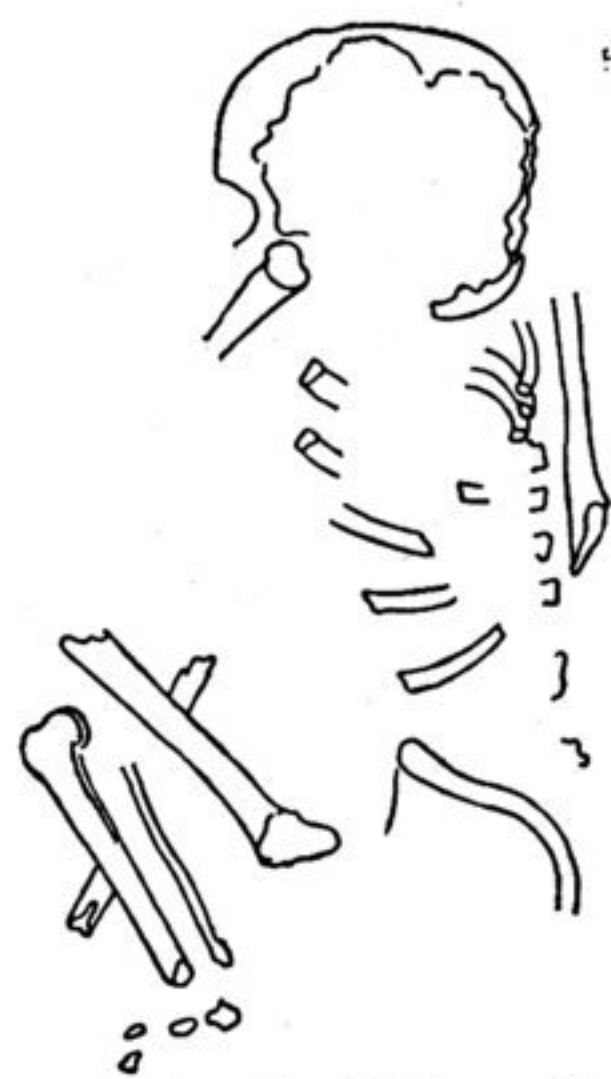

Fig. 535.—No. 2, Terrace I.

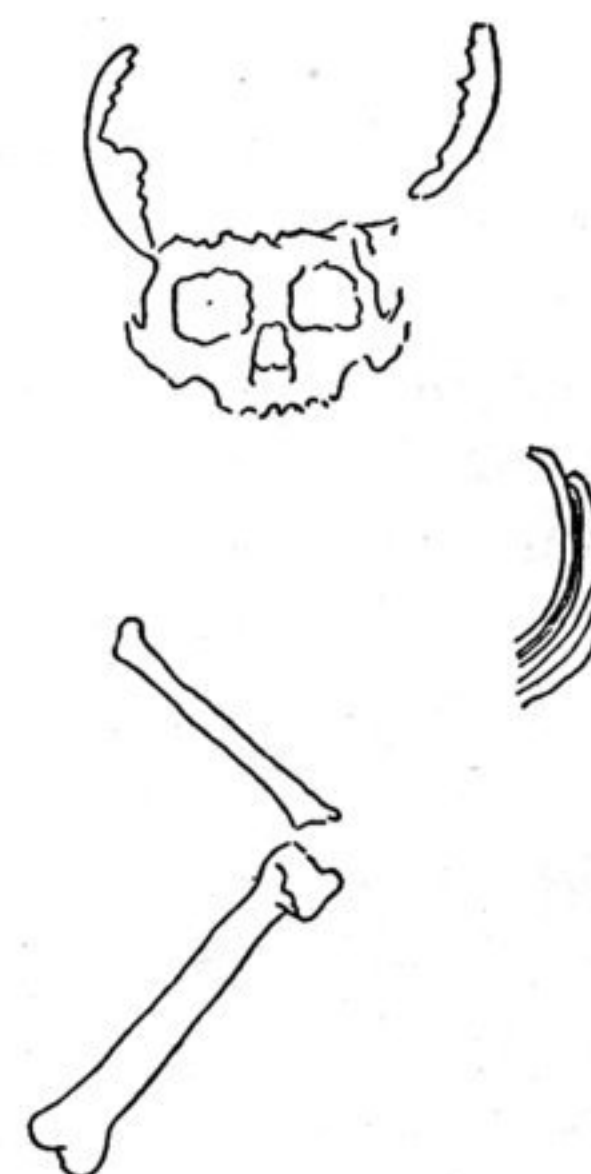

Fig. 536.—No. 3, Terrace I.

*Skeleton No. 4.*—The next burial was found at a height of +27 feet in the third terrace and more nearly approached adult size than any laid bare up to this time. The cranial sutures were not, however, closed and the ossification of the epiphyses was not complete in the limb-bones.

The body lay contracted on its right side with the main axis southeast and northwest. Both arms were drawn up as if to bring the hands (which were lacking) in front of the face, the left above the right. From the top of the badly broken cranium to the end of the spine measured 23 inches and from the back of the spine across to the ends of the leg bones was but 13 inches. (See fig. 537.)

*Skeleton No. 6.*—At a height of +26 feet in the second terrace the workmen broke with their picks into the skull of a child's body that on examination gave